

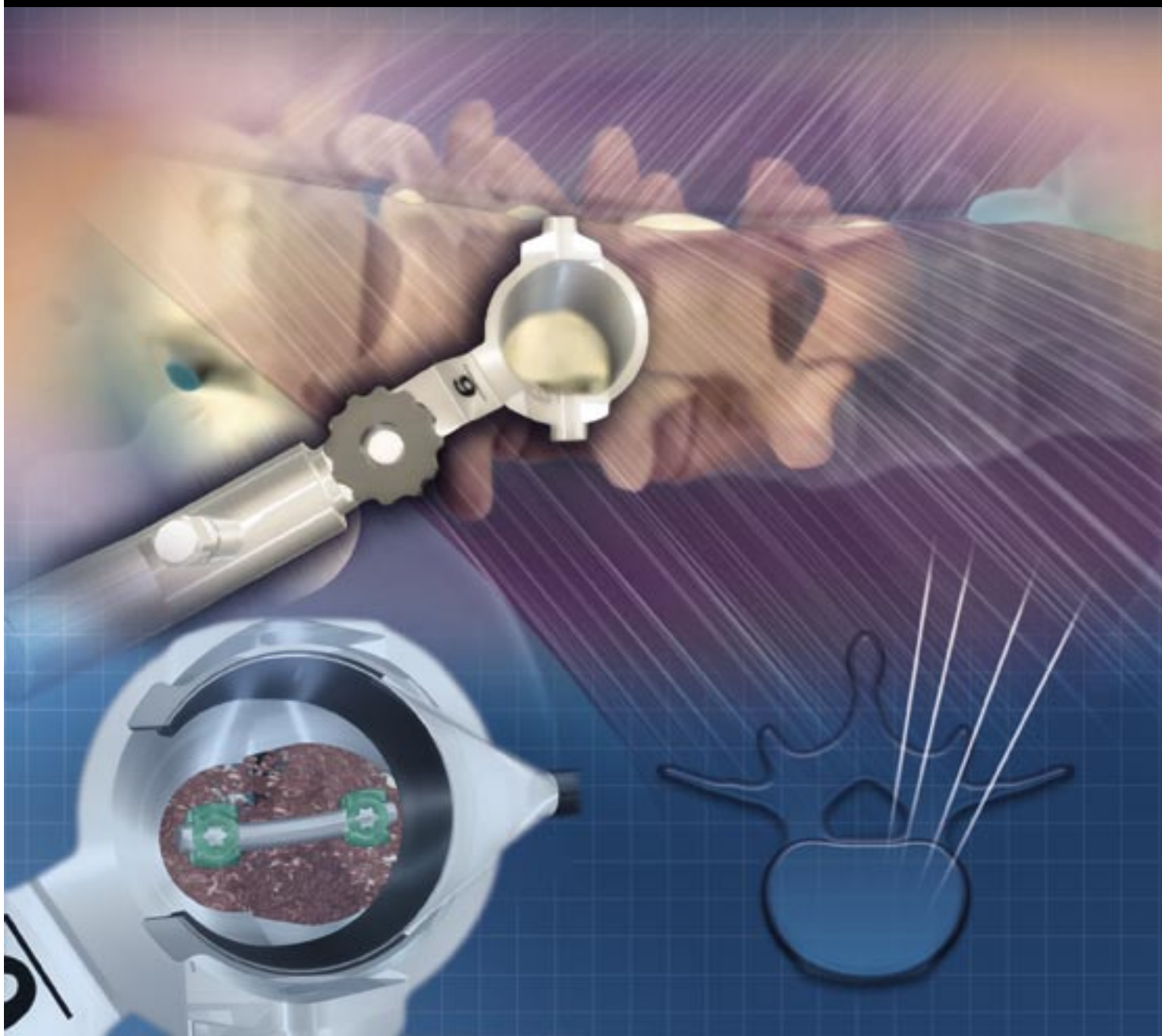

Medtronic

SOFAMOR DANEK

METRx™ System

Surgical Technique

MINIMAL ACCESS SPINAL TECHNOLOGIES™



MAST™
A NEW ROAD TO RECOVERY.



In 1997

the Micro Endoscopic Discectomy (MED) system became the

system became the

first reliable mechanism for minimally invasive access to the posterior lumbar spine. As surgical applications for this technology expanded, the MED system evolved into the Minimal Exposure Tubular Retractor (METRx) system. This tubular retractor technology has been awarded several US Patents and achieved excellent clinical results as evident in its numerous clinical publications. The following timeline helps illustrate how METRx helped pioneer the minimally invasive surgical approach.



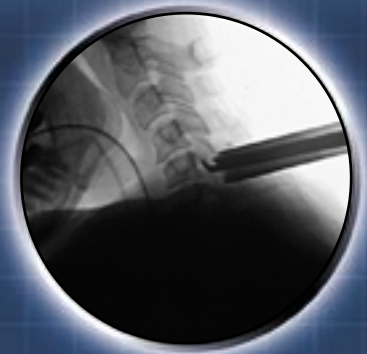1st Microendoscopic Patent Filed

1st clinical case with Micro Endoscopic Discectomy (MED) System

1996

19

1st cervical foraminotomy performed with MED system



PATENTS

6,176,823
6,206,822
6,217,509

2000

20

1st patent for Minimally Invasive Interbody Fusion filed

PATENTS

6,152,871
6,162,170
29724233.4

ARTICLE

Microendoscopic Discectomy

authored by
KEVIN T. FOLEY, MD
MAURICE M. SMITH, MD
Semmes-Murphy Clinic
Department of Neurosurgery
University of Tennessee
Memphis, Tennessee



1st Microendoscopic Discectomy patent issued

PATENTS

5,902,231
5,954,635
6,007,487

97

1998

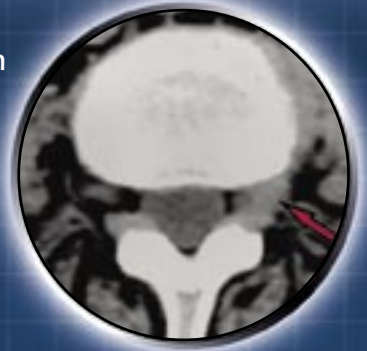
1999

ARTICLE

Microendoscopic Approach To Far-Lateral Lumbar Disc Herniation

authored by
KEVIN T. FOLEY, MD
MAURICE M. SMITH, MD
Semmes-Murphy Clinic
Department of Neurosurgery
University of Tennessee
Memphis, Tennessee
Y. RAJA RAMPERSAUD, MD
Department of Neurosurgery
University of Toronto
Toronto, Ontario, Canada

1st publish for far lateral approach with METRx



ARTICLE

Minimally Invasive Transforaminal Lumbar Interbody Fusion (TLIF): Technical Feasibility And Initial Results.

authored by
JAMES D. SCHWENDER, MD
Twin Cities Spine Center &
Department of Orthopedic Surgery,
University of Minnesota,
Minneapolis, Minnesota
LANGSTON T. HOLLY, MD
Division of Neurosurgery,
UCLA Medical Center,
Los Angeles, California
DAVID P. ROUBEN, MD
River City Orthopaedic Surgeons,
Louisville, Kentucky
KEVIN T. FOLEY, MD
Semmes-Murphy Clinic &
Department of Neurosurgery
University of Tennessee
Memphis, Tennessee

ARTICLE

Bilateral Decompressive Surgery In Lumbar Spinal Stenosis Associated With Spondylolisthesis: Unilateral Approach And Use Of A Microscope And Tubular Retractor System

authored by
SYLVAIN PALMER, MD
ROBERT TURNER, MD
ROSEMARY PALMER, RN
Mission Hospital Regional
Medical Center,
Mission Viejo, California

PATENTS

6,425,859

ARTICLE

A Minimally Invasive Technique For Decompression Of The Lumbar Spine

authored by
BERNARD H. GUIOT, MD, FRCS(C)
Department of Neurosurgery
University of Florida
Gainesville, Florida
LARRY T. KHOO, MD
RICHARD G. FESSLER, MD, PHD
Institute for Spine Care
Chicago Institute of
Neurosurgery & Neuroresearch
Chicago, Illinois

01

2002

2003

ARTICLE

Microendoscopic Posterior Cervical Laminoforaminotomy For Unilateral Radiculopathy: Results Of A New Technique In 100 Cases

authored by
TIM E. ADAMSON, MD
Carolina Neurosurgery
and Spine Associates
Charlotte, North Carolina

ARTICLE

Microdiscectomy With Minimally Invasive Tubular Retractor

authored by
DONALD LONG HILTON, JR., MD
Northeast Baptist Hospital,
San Antonio, Texas



1st patent for Minimally Invasive Interbody Fusion issued

PATENTS

6,520,907
6,679,833
2004

Targeting Using the METRx™ System

A METRx System procedure is initiated by inserting a spinal needle into the paraspinal musculature at the appropriate distance off the midline toward the bony anatomy. The placement is confirmed using lateral fluoroscopy.

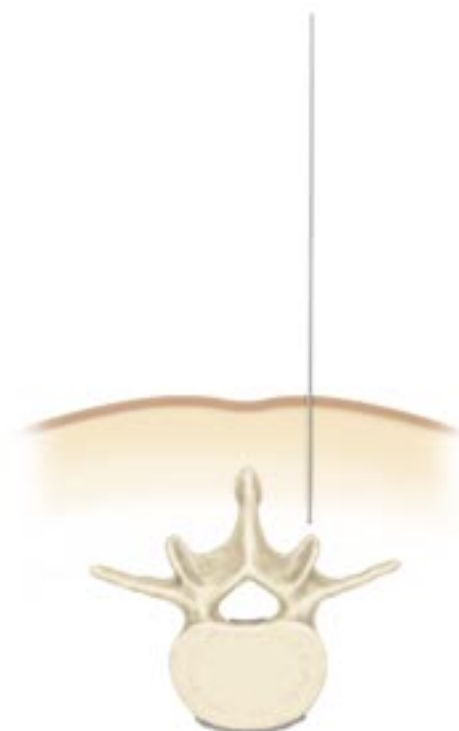
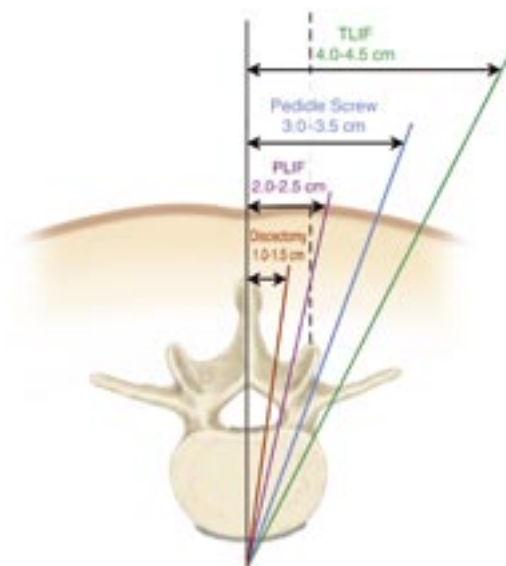
Procedure	Landmark Docking Point
Discectomy, Laminectomy, Stenosis	Inferior Aspect of the Superior Lamina
PLIF	Medial Aspect of the Facet
Pedicle Screws	Transverse Process/ Facet Junction
TLIF	Lateral Aspect of the Facet
Cervical Foraminotomy	Medial Facet/Laminar Junction
Far Lateral	Junction of TP and PARS of Superior Vertebra

Guidewire Insertion

The spinal needle is removed and a vertical incision is made at the puncture site. The incision length should match the diameter of the respective tubular retractor – 14mm tubular retractor, 14mm incision, and so on.

Some practitioners also incise the fascia to make tissue dilation easier. This is optional and can be performed later if tissue dilation is difficult.

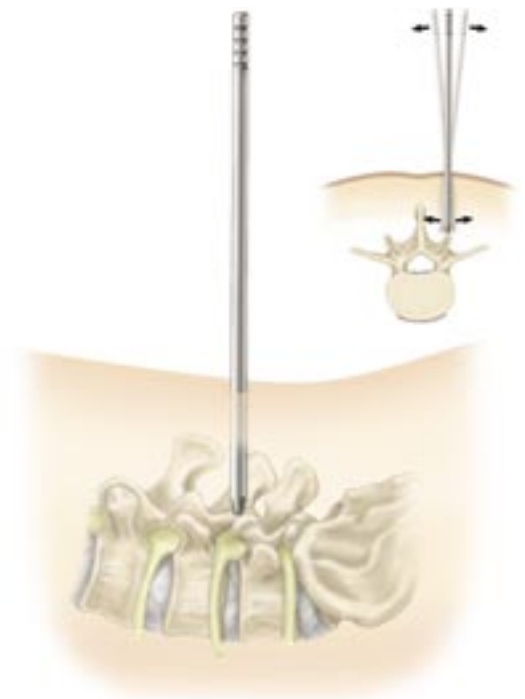The guidewire is placed through the incision and directed toward the appropriate anatomy under lateral fluoroscopy. The guidewire is advanced only through the lumbodorsal fascia. Great care must be taken to avoid penetration of the ligamentum flavum and inadvertent dural puncture with possible nerve injury or spinal fluid leak.



First Dilator Insertion

Insert the cannulated soft tissue dilator over the guidewire utilizing a twisting motion. Once the fascia is penetrated, remove the guidewire and advance the dilator down to the bony anatomy.

Use the initial dilator to palpate the anatomy in both the coronal and sagittal planes. This maneuver confirms an appropriate approach laterally and helps expedite soft tissue removal.

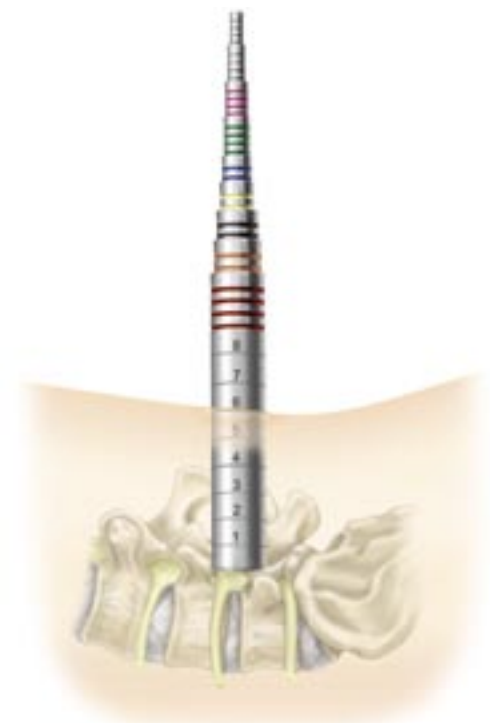

Sequential Dilation and Tubular Retractor Insertion

The next series of dilators are sequentially placed over each other. Only use the number of dilators required to get to the preferred tubular retractor diameter. The depth markings on the dilators are noted to indicate the tubular retractor length appropriate to the patient's anatomy.

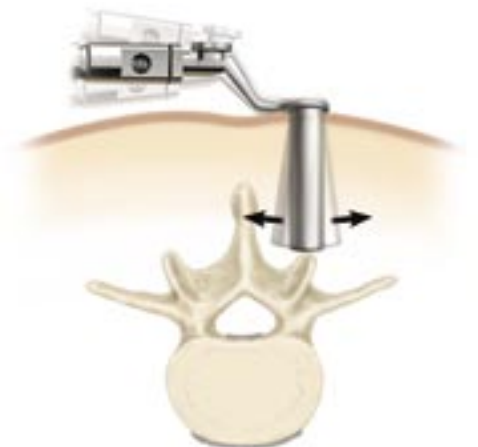
The optimum tubular retractor is placed over the sequential dilators and seated firmly on the bony anatomy. The flexible arm is attached to the bed rail and the selected tubular retractor.

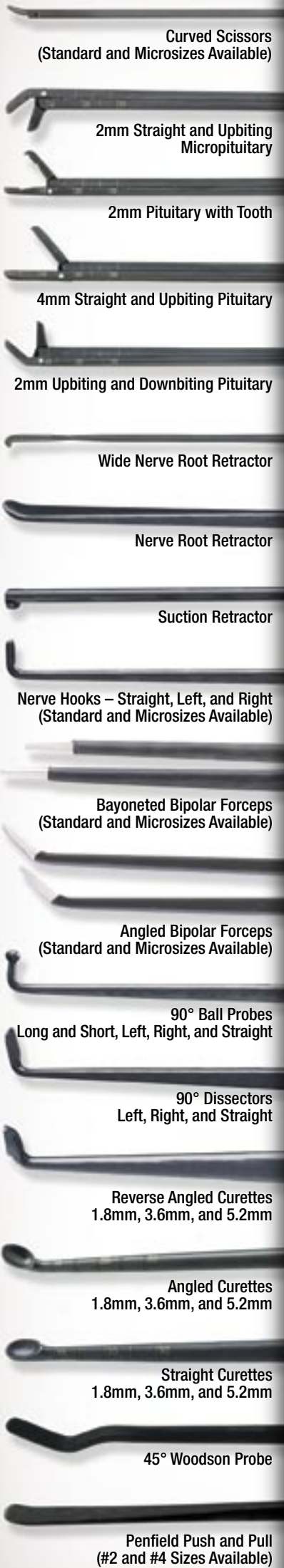The flexible arm is secured and the sequential dilators are removed, establishing a tubular operative corridor.



Repositioning the Tubular Retractor

If repositioning of the tubular retractor is necessary, the retractor can be moved or angled over the pathology by a process known as wandng. Insert the matching color dilator into the tube. While downward pressure is placed on the tubular retractor, the flexible arm is unlocked, allowing the tubular retractor to be pivoted over the desired location.





Curved Scissors
(Standard and Microsizes Available)

2mm Straight and Upbiting
Micropituitary

2mm Pituitary with Tooth

4mm Straight and Upbiting Pituitary

2mm Upbiting and Downbiting Pituitary

Wide Nerve Root Retractor

Nerve Root Retractor

Suction Retractor

Nerve Hooks – Straight, Left, and Right
(Standard and Microsizes Available)

Bayoneted Bipolar Forceps
(Standard and Microsizes Available)

Angled Bipolar Forceps
(Standard and Microsizes Available)

90° Ball Probes
Long and Short, Left, Right, and Straight

90° Dissectors
Left, Right, and Straight

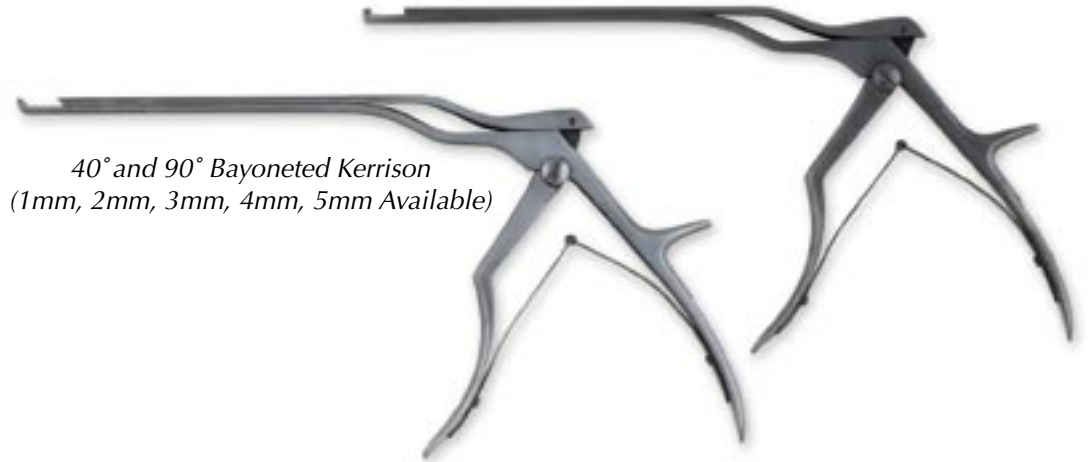Reverse Angled Curettes
1.8mm, 3.6mm, and 5.2mm

Angled Curettes
1.8mm, 3.6mm, and 5.2mm

Straight Curettes
1.8mm, 3.6mm, and 5.2mm

45° Woodson Probe


Penfield Push and Pull
(#2 and #4 Sizes Available)



40° and 90° Bayoneted Kerrison
(1mm, 2mm, 3mm, 4mm, 5mm Available)

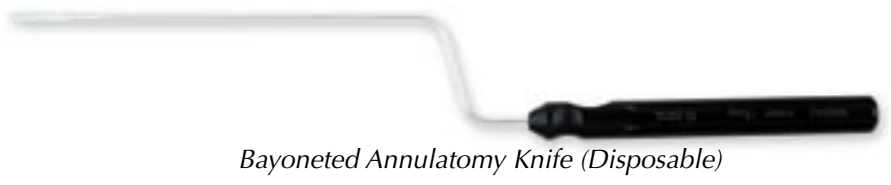

Assorted Bayoneted Instruments

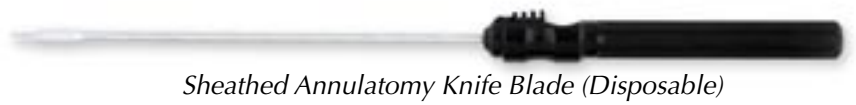

Sucker (#6, #8, #10, and
Suction Retractor Available)

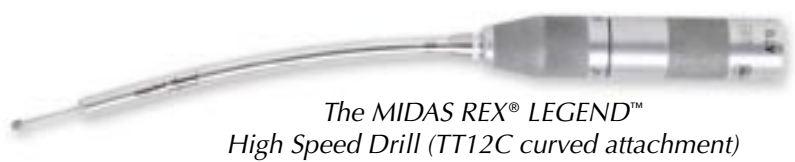Bayoneted Bovie (Disposable)



Bayoneted Annulotomy Knife (Disposable)

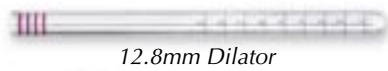

Sheathed Annulotomy Knife Blade (Disposable)



The MIDAS REX® LEGEND™
High Speed Drill (TT12C curved attachment)





12.8mm Dilator



3cm to 9cm Length
14mm Diameter



14.8mm Dilator



3cm to 9cm Length
16mm Diameter



Flex arm
assembly



Flex arm with
self-retaining
retractors



20.8mm Dilator



3cm to 9cm Length
22mm Diameter
(Stainless and Disposable Available)



22.8mm Dilator



24.8mm Dilator



3cm to 9cm Length
26mm Diameter
(Stainless and Disposable Available)



16.8mm Dilator



3cm to 9cm Length
18mm Diameter
(Stainless and Disposable Available)



18.8mm Dilator



3cm to 9cm Length
20mm Diameter



24.8mm Dilator



X-TUBE™ Retraction
4cm to 8cm Length
26mm Diameter
(Stainless and Disposable Available)



.062 x 12"
Guidewire

5.3mm
Dilator

9.4mm
Dilator

Patient Positioning and Room Set-up

METRx posterior cervical foraminal access is performed in a similar stepwise fashion as described in the previous posterior lumbar steps with the following exceptions:

Anatomic location – cervical spine

Patient position – the patient is placed in a Mayfield pin holder with frame extended as far as possible to allow adequate AP fluoroscopic visualization. The fluoroscope is rotated so the line of view is perpendicular to the spinal laminar line. Generally the fluoroscope will come in from the surgeon's right, the surgeon being seated directly at the patient's head (Figure 1) when the tubular retractor is safely docked in operating position the fluoroscope can be moved to allow the microscope to be brought in.

Guidewire Insertion – A 20-gauge spinal needle is inserted into the paraspinal musculature approximately 1 cm to 2 cm off midline at the appropriate level. The AP fluoro will allow the surgeon to safely access the lateral mass and stay clear of the canal. A stab wound is made over the needle puncture site and the localizing guidewire is passed down below the fascia. The guidewire is advanced through the deep cervical fascia (Figure 2). It is not necessary to purchase the guidewire on the bone of the lateral mass. If this is done extreme care should be taken to make certain the guidewire is safely docked well lateral on the lateral mass.

Dilator Insertion – Posterior cervical soft tissue is slightly more dense and requires more care to be taken as dilators are rotated incrementally down to the lateral mass until the desired tubular retractor is in place (Figure 3).

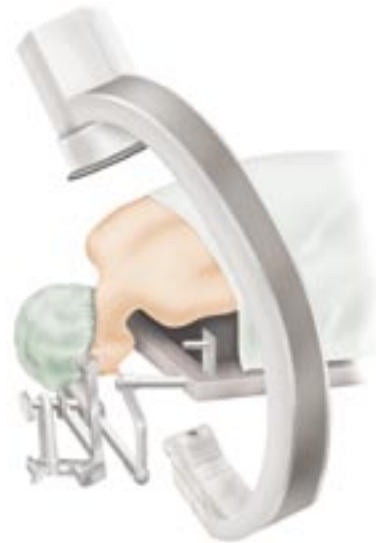

Figure 1

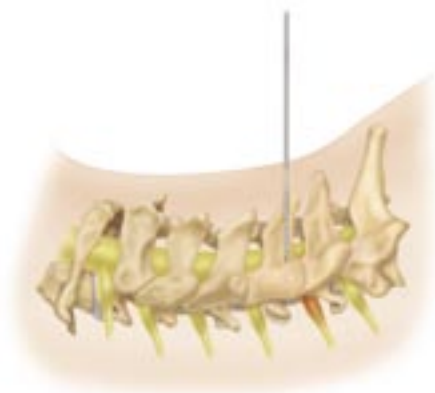

Figure 2

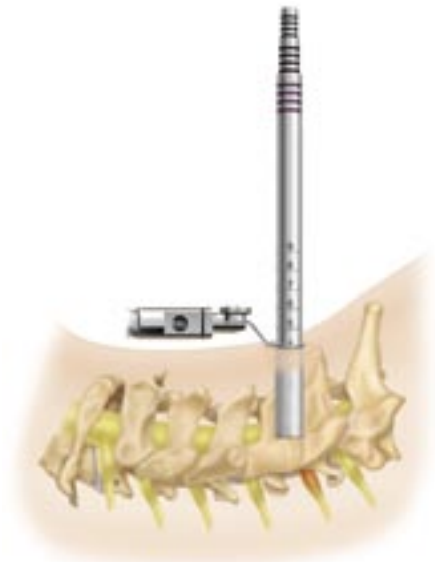


Figure 3

Soft Tissue Removal and Lamina Identification

The soft tissue over the lamina and intralaminar space is removed with an extended Bovie on low power and pituitary rongeurs (Figure 4). If the tube is correctly positioned the junction of the two lamina with the medial facet should be seen in the tube (Figure 5). The initial laminar bites are taken in the caudal lamina in a caudal then lateral and then cranial direction as the cranial lamina edge is addressed last (Figure 6). The bony work should continue until each pedicle is exposed.

Cervical Root Identification and Disc Removal

With bipedal exposure the axilla is generally explored first. Frequently a soft disc will be completely removed through the axilla. Occasionally more cranially located fragments will have to be removed through the shoulder. The cervical penfield and hook can be used to gently retract the root in the axilla (Figure 7). The disc will frequently be seen in this location. The bayonnetted knife may be used to incise the ligament as needed. The longer hook may be used to explore the foramen after removal of the disc. Cotton patties may be used to obtain hemostasis along with microbipolar forceps.

Closure

After the root is decompressed this site is irrigated thoroughly with saline. The flexible arm should then be loosened and the retractor slowly removed incrementally. Bleeding should be progressively controlled with bipolar coagulation as the retractor is withdrawn.

It is generally impossible to close the fascia. Subcuticular closures are done in an inverted manner and Steri-Strips or a Band-Aid may then be used as desired. Dermabond is also frequently used.

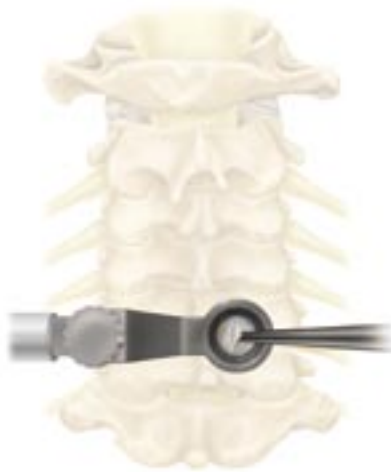

Figure 4

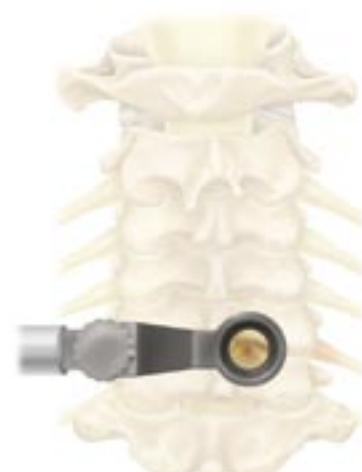

Figure 5

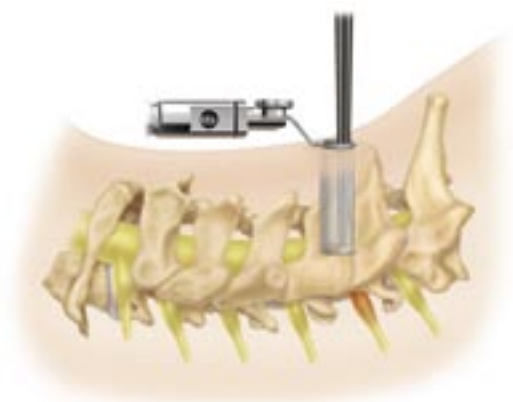


Figure 6

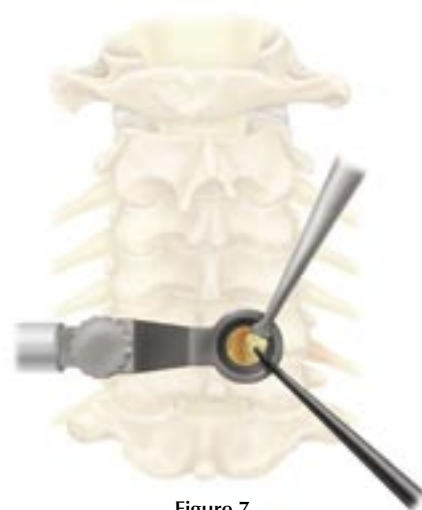

Figure 7



Medtronic
SOFAMOR DANEK

See METRx Brochure for steps that precede this technique (Part# LITMTXST4)

Soft Tissue Removal and Laminar Identification

It is essential to remove all soft tissue exposed in the operative corridor in order to maximize the working space within the tubular retractor. This can be accomplished with a pituitary rongeur and/or electrocautery.

The laminar edge is identified and the ligamentum flavum is detached from the undersurface of the lamina with a small angled curette (Figure 1).

Laminar and Interlaminar Space Identification

A hemilaminotomy/medial facetotomy is then performed with a Kerrison punch or high speed drill (Figure 2). Lateral recess and/or foraminal stenosis can be addressed in this fashion. Effective utilization of lateral fluoroscopy will help tailor the dissection as necessary to access specific pathology. When the decompression is done mainly for lumbar stenosis and not a disc herniation, the laminotomy is carried just cephalad to the insertion of the ligamentum flavum onto the underside of the lamina. This assures that all hypertrophied ligamentum will be removed, adequately decompressing the canal. If the pathology is beyond the confines of the tubular retractor, wandung can be used to reposition the tubular retractor.

Ligamentum Flavum Removal

The ligament is penetrated with the curette or ball probe utilizing a twisting motion under the remaining superior lamina where the ligament is thin (Figure 3). It is peeled back caudally and dorsally, then resected with a Kerrison punch (Figure 4).

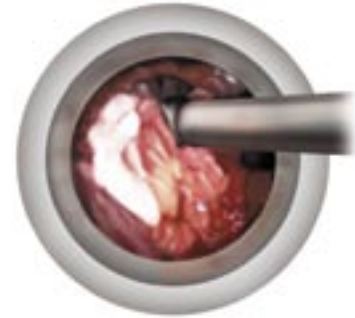


Figure 1

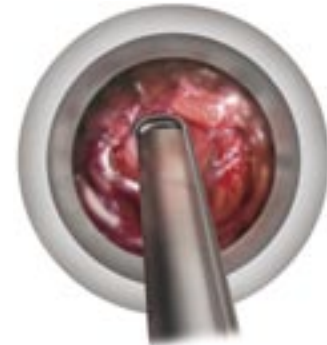

Figure 2

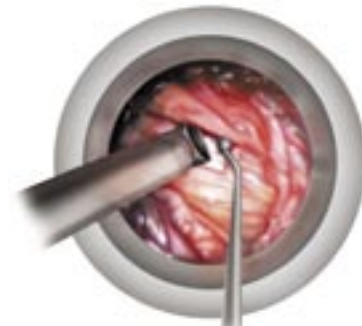


Figure 3

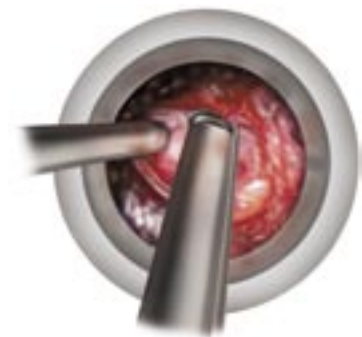


Figure 4

Nerve Root Exploration and Retraction

There is an initial tendency to “cone” the exposure down to the final target reducing the working space and visualization in the tubular retractor. In order to avoid this, it is important to complete soft tissue, bone and ligament removal over the entire area of the exposure. Figure 5 shows appropriate exposure of the epidural space.

The dura and traversing nerve root are identified. The nerve root is retracted medially utilizing a penfield dissector, Love style or suction retractor (Figure 5). The volar epidural space can then be explored. If necessary, epidural veins can be cauterized with bipolar forceps and divided with micro scissors (Figure 6). Cotton patties can also be used to obtain hemostasis.

Discectomy and Closure

Identify the disc herniation. If an annulotomy is necessary, it can be accomplished with the annulotomy knife while protecting the nerve root with the retractor. The herniated disc is then removed with a pituitary rongeur in a standard fashion (Figure 7). Intradiscal and extradiscal work can be carried out as one would normally perform during an open microdiscectomy. The nerve root is explored to ensure the decompression is complete.

Once the nerve root is decompressed, irrigate the disc space thoroughly. Epidural steroids may be injected if desired. Loosen the flexible arm assembly and slowly remove the tubular retractor. Any bleeding in the paraspinal musculature can be controlled with the bipolar as the tube is removed.

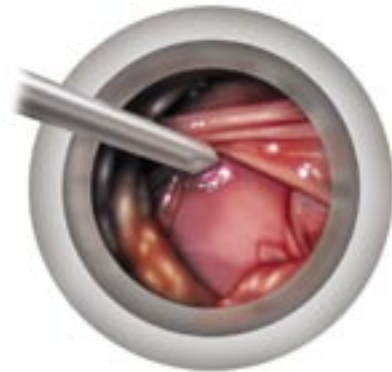

Figure 5

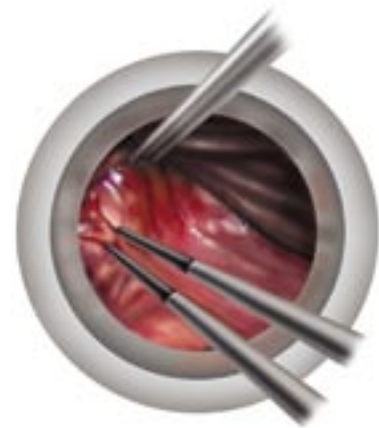

Figure 6

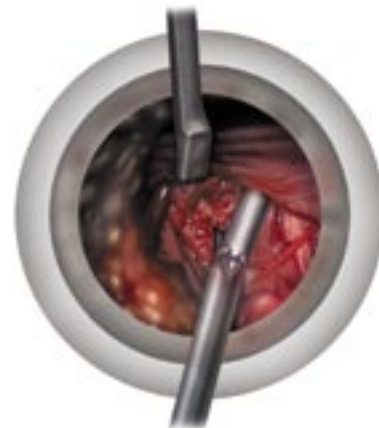

Figure 7



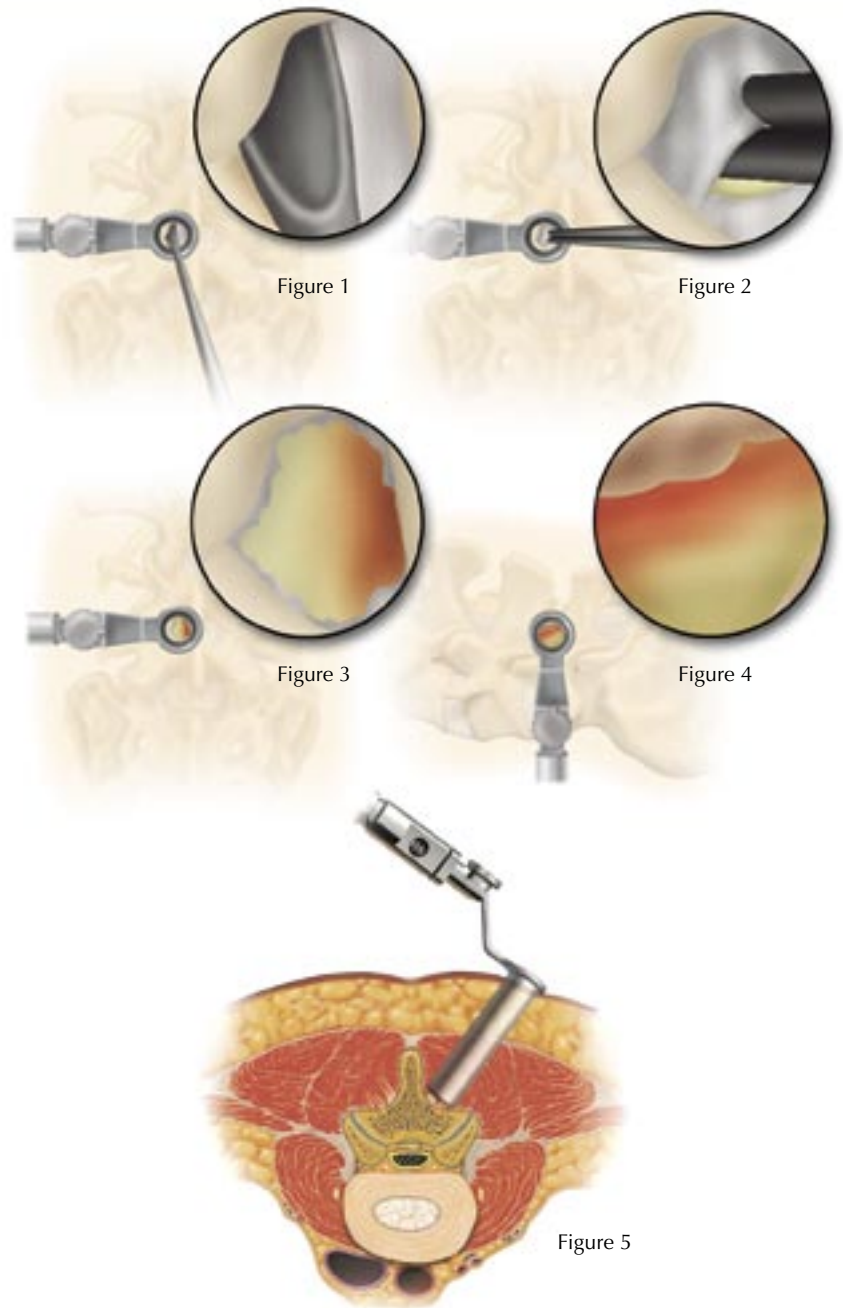
Medtronic
SOFAMOR DANEK

Decompression

In preparation for a spinal stenosis procedure, insert the appropriate-sized METRx System tube as described in the METRx System Surgical Technique. Once the tube is positioned, it is important to extend the laminotomy cephalad above the insertion of the ligamentum flavum. This is to insure resection of all hypertrophied ligamentum. After the cephalad border of the ligamentum is exposed it can be separated from the dura using angled curettes or a right or left ball tip dissector (Figure 1). The ligamentum is then resected with a 90° or 40° Kerrison punch (Figure 2). To insure complete decompression of the lateral recess, the lateral exposure should allow palpation of the inferior pedicle. This often requires resection of the superior border of the lower lamina (Figure 3). It will also remove any caudal residual ligamentum, which often can compress the dura or nerve root. Foraminotomies are then performed, as necessary, to decompress both exposed foramina (Figure 4). The ball tip probe should be able to pass freely into both the cephalad and caudal foramina.

After achieving the ipsilateral decompression, a separate contralateral exposure may be utilized to decompress the opposite lateral recess by following the aforesaid procedural steps (Figure 5).

See METRx Brochure for steps that precede this technique (Part# LITMTXST4)



Contralateral Decompression from an Ipsilateral Approach

As an alternative to contralateral decompression from the contralateral side, an ipsilateral approach to contralateral decompression can be utilized. After completion of the ipsilateral decompression the tubular retractor is angled medially to expose the anterior spinous process. A drill can then be utilized to resect the anterior spinous process and the medial aspect of the contralateral lamina (Figure 6). This exposes the contralateral hypertrophied ligamentum flavum, which can then be resected using Kerrison punches and curettes (Figures 7a, 7b and 7c). Care is taken to palpate the caudal pedicle and probe both the cephalad and caudal foramina to be certain that the decompression is complete (Figure 8).

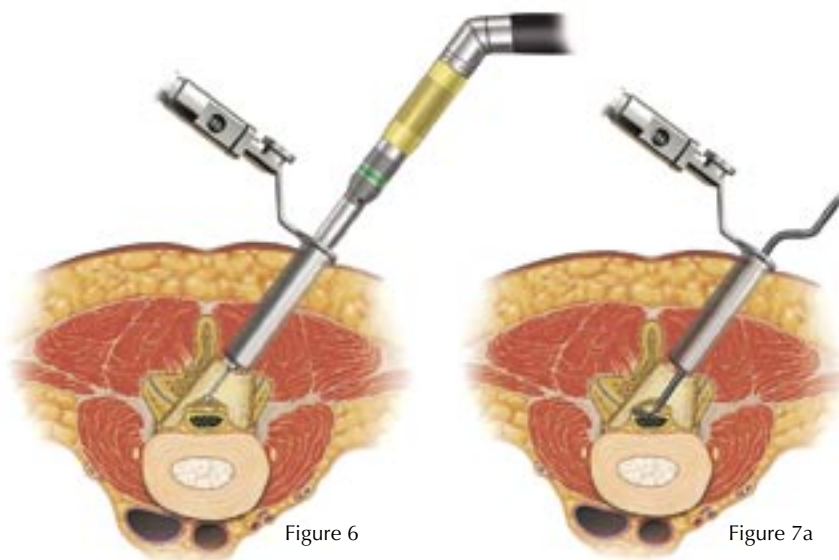


Figure 6

Figure 7a

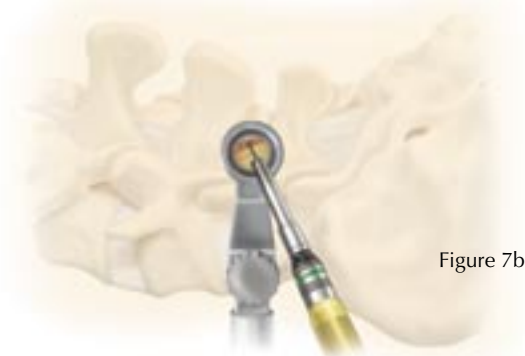

Figure 7b

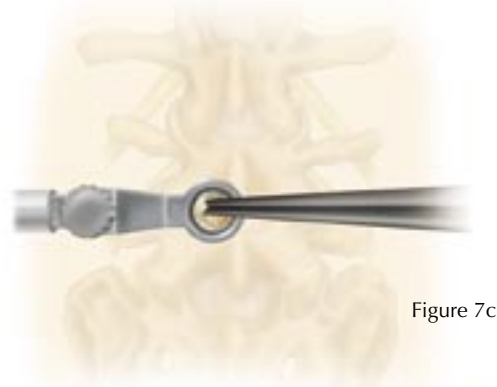


Figure 7c

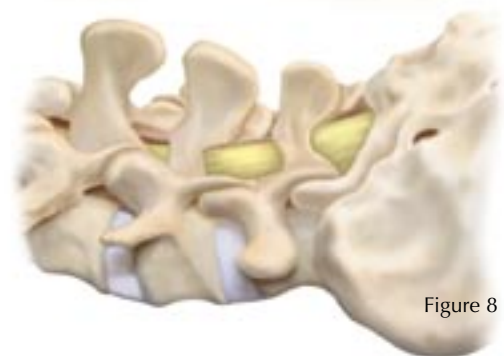

Figure 8

MEDTRONIC SOFAMOR DANEK USA, INC.
1800 Pyramid Place, Memphis, TN 38132
(901) 396-3133 (800) 876-3133
Customer Service: (800) 933-2635

www.sofamordanek.com



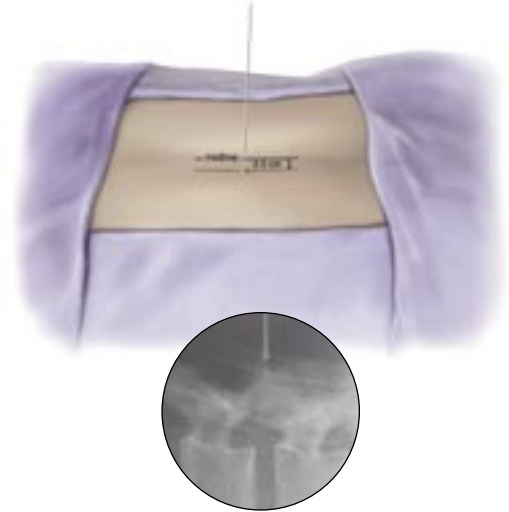See METRx Brochure for steps that precede this technique (Part# LITMTXST4)

Preoperative Planning

The patient is placed on the operating table in the prone position with lateral C-arm fluoroscopy. Care should be used to maintain the patient in a lumbar lordotic position.

Spinal needle is placed into paraspinous musculature 2–2.5cm off of midline at the appropriate level confirmed using lateral fluoroscopy.

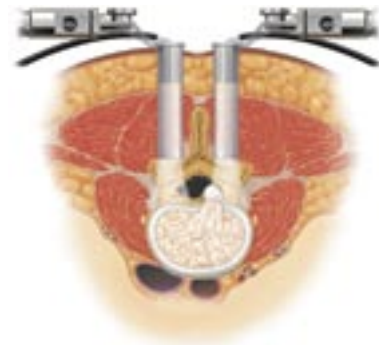
The Guidewire is placed through the incision and directed toward the facet under lateral fluoroscopy.



Dilation/tubular retraction

Insert initial cannulated soft tissue Dilator over the Guidewire. Once the fascia is penetrated, remove the Guidewire and advance the Dilator over the facet. Confirm the placement of initial Dilator using lateral fluoroscopy.

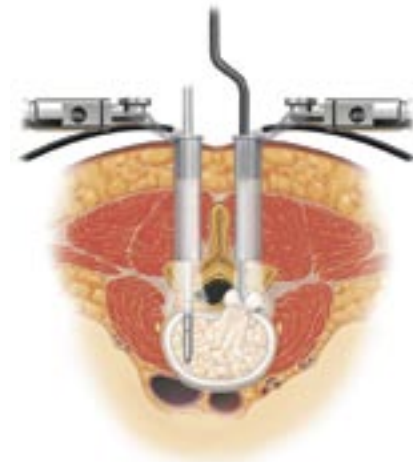
Sequential Dilation and Tubular Retractor Insertion



Laminotomy, Facetectomy, & Discectomy

A conventional discectomy is performed by incising the annulus with a 15-scalpel blade lateral to the dural sac.

This is done bilaterally and then soft fragments from the intradiscal space or extruded fragments are removed with Disc Rongeurs in a conventional fashion.



Disc space distraction

The disc space is sequentially distracted until original disc space height is obtained and normal foraminal opening is restored.

Insert the Distractor with the T-handle attached, with the flat surface parallel to the endplates.

Rotate the Distractor 90 degrees to distract the space and remove the T-handle.

Sequentially insert Distractors from side to side until the desired height is obtained.

The largest Distractor is left in the disc space in the distracted position while continued disc space preparation is performed.

Disc space preparation

The smallest Rotate Cutter is inserted into the disc space with the cutting blades parallel to the dural sac.

The Rotate Cutter is rotated once or twice at a depth of 20mm to remove osteophytes at the dorsal endplate. Removing osteophytes facilitates placement of the Cutting Chisel later in the procedure.

The Rotate Cutter is then inserted up to a depth of 30mm and rotated to remove residual intradiscal material.

Remaining soft tissue or cartilaginous endplate covering are removed with vigorous scraping or curettage.

Scrape medially under the midline and gradually work laterally in a sweeping motion until both caudal and cephalad endplates are cleared of soft tissue.

The removal of the soft tissue from the endplate surface allows optimal graft incorporation.

Endplate Preparation

With the dura protected or minimally retracted, the lateral extensions of the Cutting Chisel are seated into the disc space.

Place the lateral edge of the Cutting Chisel on or lateral to the mid-sagittal line of the pedicle.

The Chisel is impacted into the disc space. The cutting blades will remove the residual osteophytes and create an optimal bed to receive the wedge.

To insert a 26mm graft, repeat the process and insert the Chisel to a depth of 35mm.

After impacting the Cutting Chisel up to a depth of 30mm, attach the Slap Hammer to the Chisel handle and rotate 90 degrees and remove the Chisel with a repeated gentle upward stroke.

Wedge Insertion

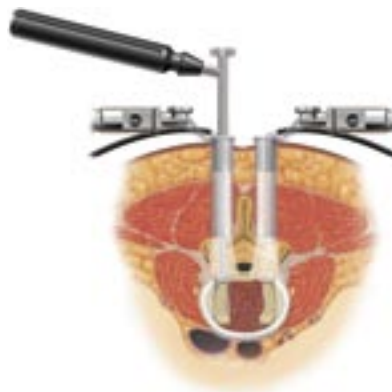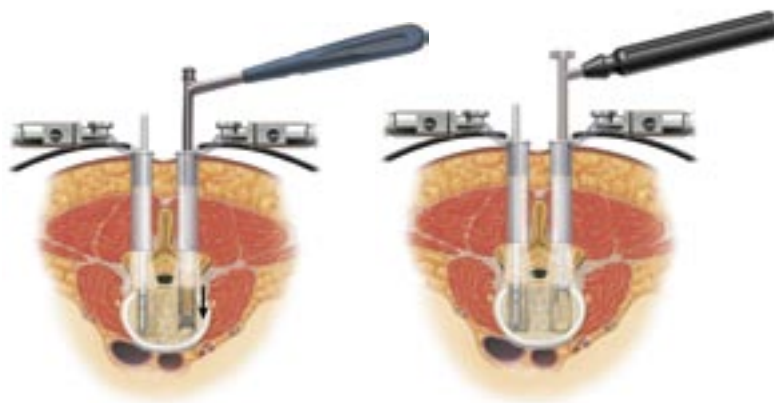
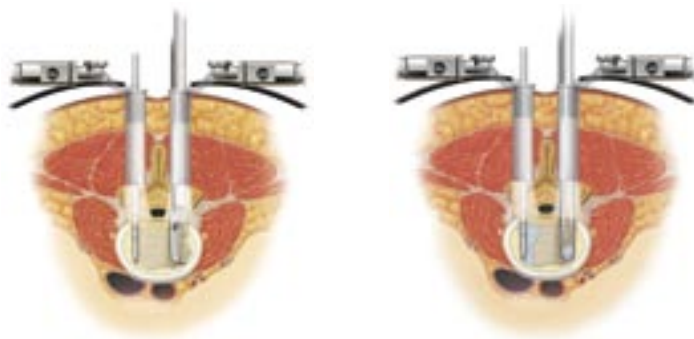The appropriate size allograft wedge is firmly attached to the Inserter.

Gently impact the wedge down the previously prepared channel until it is 3 to 4mm below the posterior margin.

Once the wedge has been inserted on the contralateral side, the first Disc Distractor is removed. Morselized autograph acquired from local bony elements or the iliac crest is then packed into the prepared disc space beneath the midline structures.

The second Wedge is inserted into the disc space along the previously prepared track.

After the final wedge is placed, the extradural space and foramina are probed to ensure adequate decompression of the neural elements.



Medtronic
SOFAMOR DANEK

©2004 Medtronic Sofamor Danek USA, Inc. All Rights Reserved.

MEDTRONIC SOFAMOR DANEK USA, INC.
1800 Pyramid Place, Memphis, TN 38132
(901) 396-3133 (800) 876-3133
Customer Service: (800) 933-2635

www.sofamordanek.com

Incorporates technology developed by Gary K. Michelson, M.D.



See METRx Brochure for steps that precede this technique (Part# LITMTXST4)

METRx Device Placement and Spinal Preparation

To initiate spinal cord stimulator electrode placement, the METRx System tube is inserted as described in the METRx System Surgical Technique Guide. Once the tube is positioned, it is important to extend the laminotomy cephalad above the insertion of the ligamentum flavum (LF). This is to insure resection of all hypertrophied ligamentum. After the cephalad border of the LF is exposed it can be separated from the dura using angled currettis or a right or left ball tip dissector (Figure 1). A small hemi-laminotomy is then performed with use of various sized and angled Kerrison punch instruments and currettis (Figure 2).

The underlying LF is also resected to expose the dural surface. It is important that the medial border of the hemi-laminectomy extend as close to midline as possible in order to facilitate placement of the paddle lead. To allow for easier lead advancement and less dural compression, a paramedian oblique approach and “wandering” of the METRx tube to lessen the angle in relation to the spinal column can be employed up to 30° lateral and 30° caudal (Figure 3A, 3B and 3C).

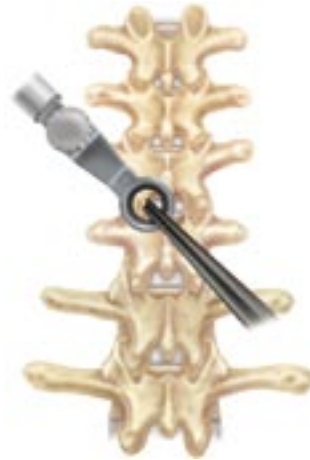

Figure 1



Figure 2

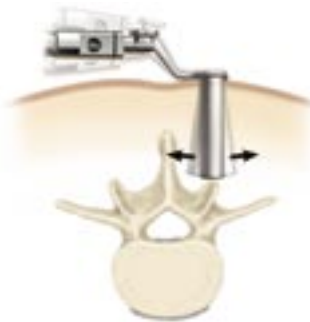


Figure 3a

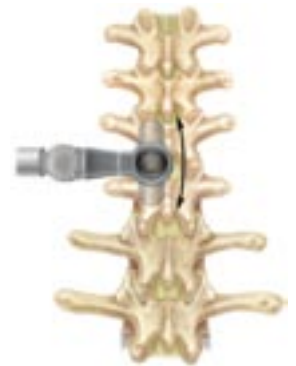

Figure 3b

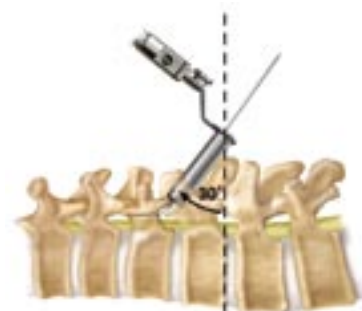

Figure 3c

Lead Implantation

Clear any epidural scarring/adhesions with the epidural passing elevator or Penfield dissector. The paddle lead is then placed in the epidural space and advanced in a cephalad direction (Figure 4). The precise lead position is confirmed with fluoroscopy in AP and lateral views (Figure 5A and 5B) or through awake trial stimulation. After the lead is properly positioned, the paddle lead wires are secured to fascia or bone surrounding the adjacent facet with nonabsorbable suture. The METRx working tube is then removed from the wound taking care not to dislodge the lead wires (Figure 6). It is also an option to anchor to the fascia overlaying the paraspinal muscles after the tube is removed. The fascia overlying the paraspinal muscles are reapproximated with suture. The paddle lead wires can then be tunneled to the chosen generator pocket area.

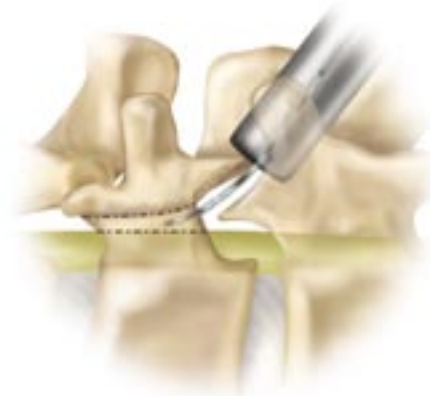

Figure 4

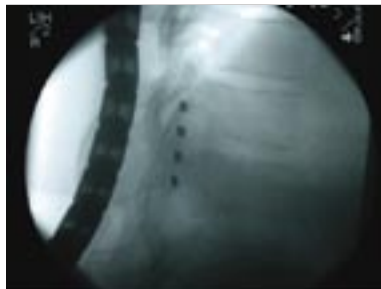


Figure 5a

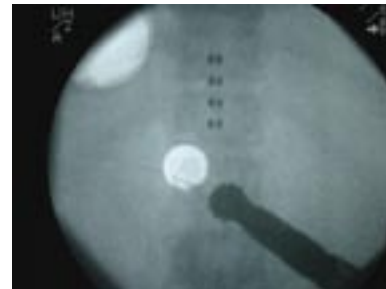

Figure 5b

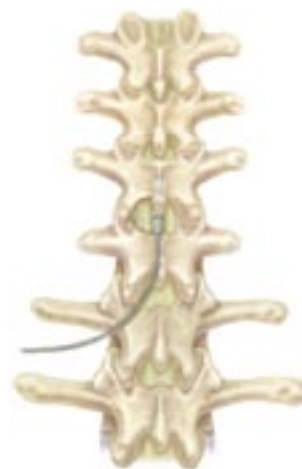

Figure 6

MINIMAL ACCESS SPINAL TECHNOLOGIES™

See METRx Brochure for steps that precede this technique (Part# LITMTXST4)

Soft tissue dilation and bony exposure

In a TLIF procedure, a larger diameter 22 or 26mm METRx tube is use to access the ipsi-lateral side following tissue dilation. Once the tube is positioned, remove the superior and inferior facet using an osteotome or drill. It is important to remove the entire facet in order to provide a better view and access to the disc space. Additional bony removal may be carried out at this time using a Kerrison Rongeur or drill. Use caution not to violate pedicle walls (Figures 1, 2, 3)



Figure 1

Figure 2

Disc removal

Incise the disc space with a scalpel and begin disc removal using a Pituitary Rongeur. Continue disc removal using either the Straight or Curved Rotating Cutters. The Rotating Cutters are blunt tipped and side cutting to ensure safety. A T-handle or a hand held power drill may be used for more efficient removal of disc (Figures 4, 5).

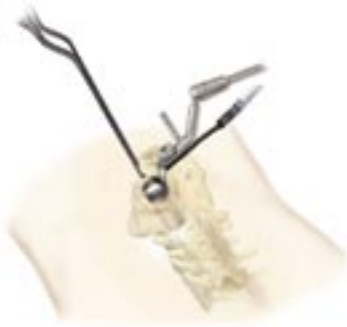

Figure 3

Contralateral screw insertion

Insert CD HORIZON® Cannulated M8 Multi-Axial Screws using the CD HORIZON® SEXTANT™ Rod Insertion System on the contralateral side. The screws are used to maintain distraction during disc space preparation (Fig 6).

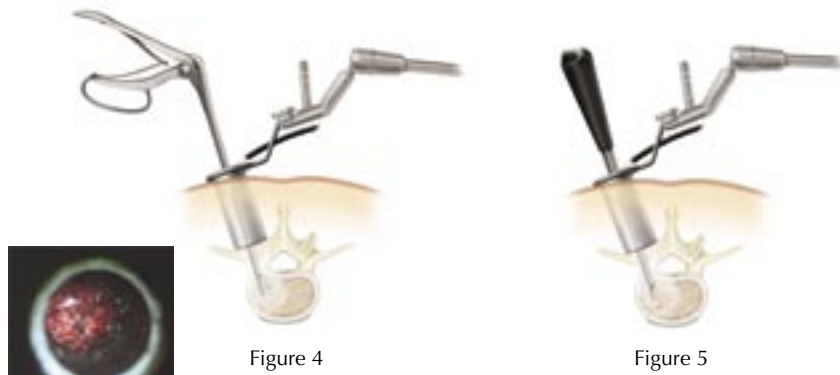


Figure 4

Figure 5

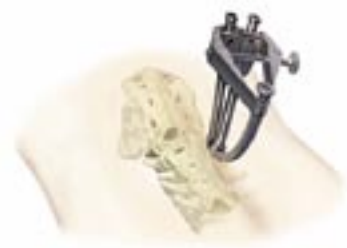

Figure 6

Restoration of disc space height

Reestablish disc space height by using either the Impacted Distractors or the Expanding Distractor. Once adequate distraction has been obtained via the interbody space, provisionally tighten the contra-lateral screws (Figure 7).

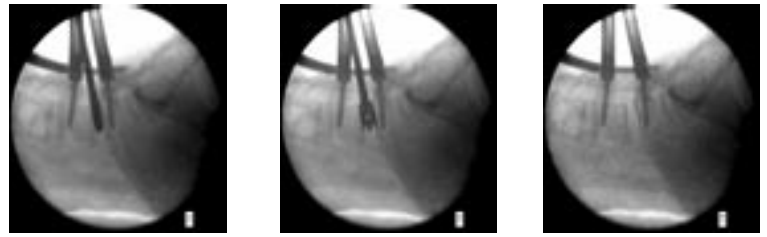


Figure 7

Endplate preparation

Using various curettes & scrapers, remove the cartilaginous material from the disc space & the endplates. Continue preparation of the bony endplates using curettes, scrapers, and rasps. Specially designed angled instruments allow disc resection and endplate preparation on the contra-lateral side (Figure 8).

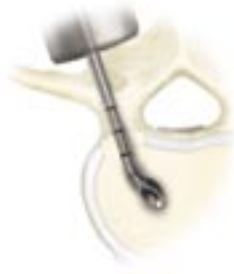

Figure 8

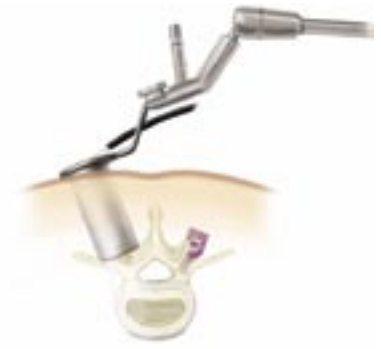

Figure 9

Interbody construct insertion

Choose the appropriate size implant based on the use of the trial sizers (Figure 9).

Compression

Apply compression to the contra-lateral screws. Break-off set screws to maintain compression on the interbody device (Figure 10).



Figure 10

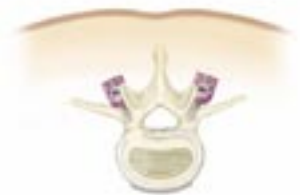

Figure 11

Ipsilateral screw insertion

Ipsi-lateral instrumentation may be inserted percutaneously or via direct visualization through the METRx™ Tube (Figure 11).

MEDTRONIC SOFAMOR DANEK USA, INC.
1800 Pyramid Place, Memphis, TN 38132
(901) 396-3133 (800) 876-3133
Customer Service: (800) 933-2635

www.sofamordanek.com



XTube Introduction

A METRx™ X-Tube is selected in accordance with exposed markings on the final dilator (Figure 1). The X-Tube is then inserted over the dilators and seated firmly flush with the bony anatomy and locked in place with the flexible arm. The dilators are then removed establishing a tubular operative corridor.

XTube Deployment

X-TUBE is inserted over dilators and seated firmly flush with bony anatomy and locked in place with the flexible arm. Dilators are removed establishing a tubular operative corridor (Figure 2).

See METRx Brochure for steps that precede this technique (Part# LITMTXST4)

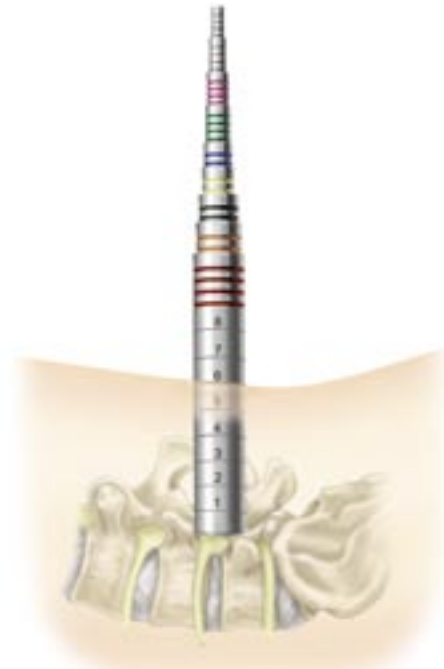

Figure 1

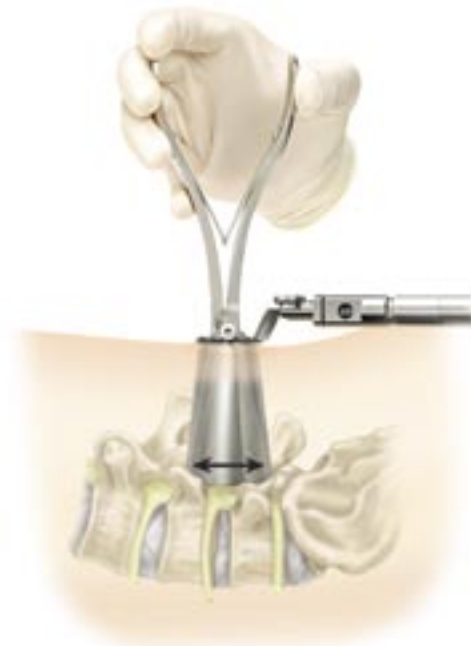

Figure 2

Pedicle Preparation

Inferior and superior pedicles may now be targeted (Figure 3).

Screw Insertion

Tap and insert pedicle screw (Figure 4).

Rod Insertion

Using MAST LEGACY inserter, rod may now be inserted (Figure 5).

Compression

Compression and/or distraction may be accomplished using the respective instruments from MAST LEGACY (Figure 6).

XTube Extraction

The X-Tube is closed by turning the opener instrument 90 degrees so the stops are perpendicular to the hinges (Figure 3). The opener is then compressed causing the X-Tube to collapse (Figure 7).

Conclusion

The objective of the METRx™ System is the same as conventional open surgery. This is accomplished by applying open surgical techniques through a tubular retractor under microscopic, loupes, or endoscopic visualization. For the first time, a laminotomy, medial facetectomy, foraminotomy, discectomy, PLIF, TLIF, posterior lateral fusion, or pedicle screw insertion can be performed in a minimally invasive fashion.

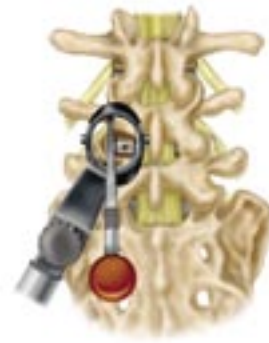

Figure 3

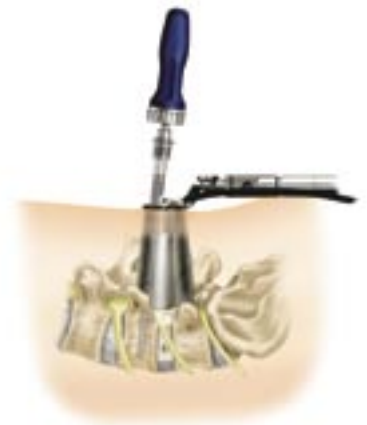

Figure 4

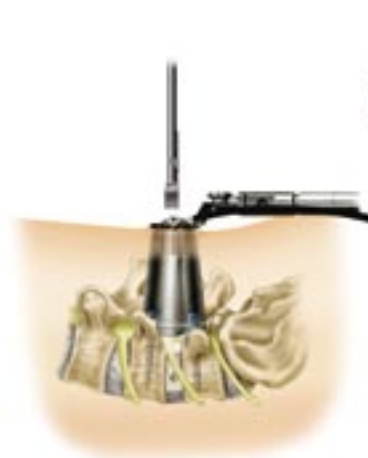

Figure 5

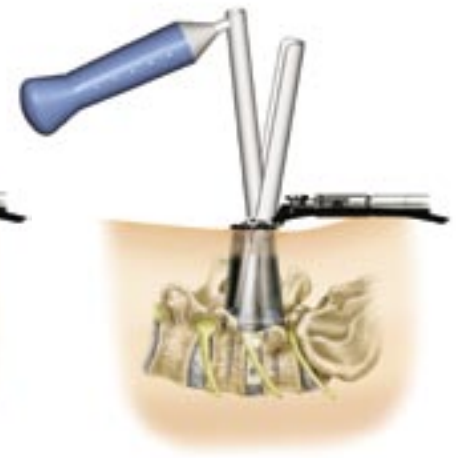

Figure 6

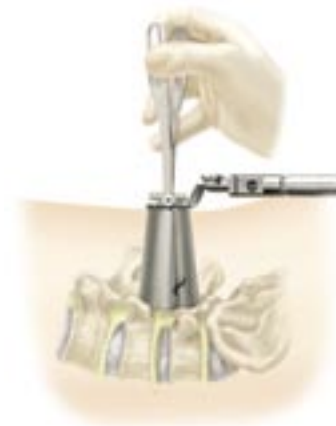

Figure 7



Medtronic
SOFAMOR DANEK



**RADIANCE™
Illumination
System**



**RADIANCE X™
Illumination
System**



**18, 22, and 26mm
Disposable Tubes**

**Microdissection and
MicroEndoscopic
Dissection
Procedure Kits**



**METRx X-TUBE
Retraction System**



**METRx Micro
Instrumentation**



METRx Large Tube System



Medtronic
SOFAMOR DANEK

MEDTRONIC SOFAMOR DANEK USA, INC.
1800 Pyramid Place Memphis, TN 38132
(901) 396-3133 (800) 876-3133
Customer Service: (800) 933-2635